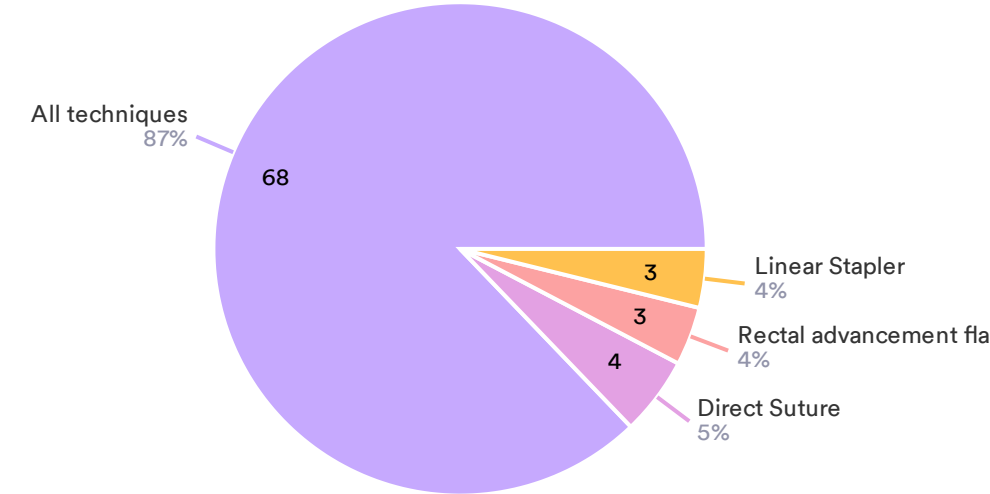


Final Test Report

Masterclass on Proctology and Pelvic Floor Diseases 2021

1) In VAAFT technique, as described in literature, the internal orifice is closed by means of

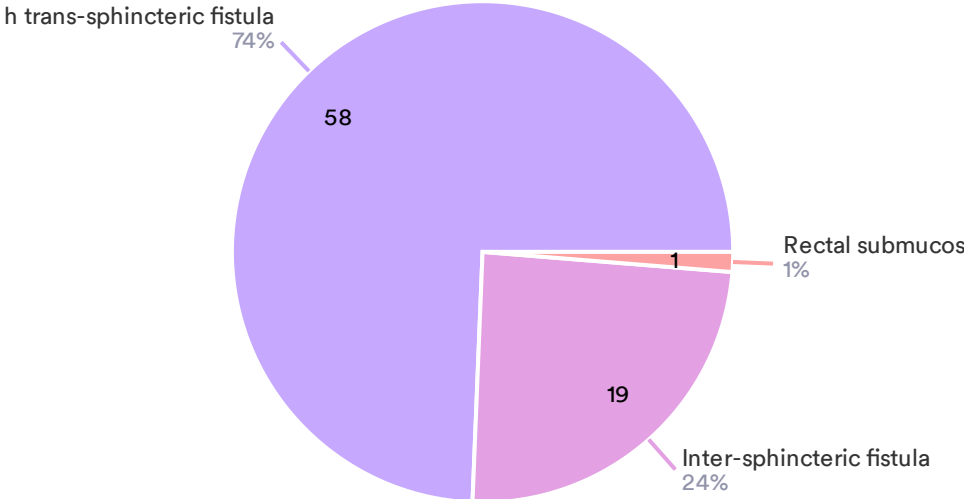
78 Responses



● All techniques ● Direct Suture ● Rectal advancement flap ● Linear Stapler

2) Laser treatment of anal fistula is indicated in

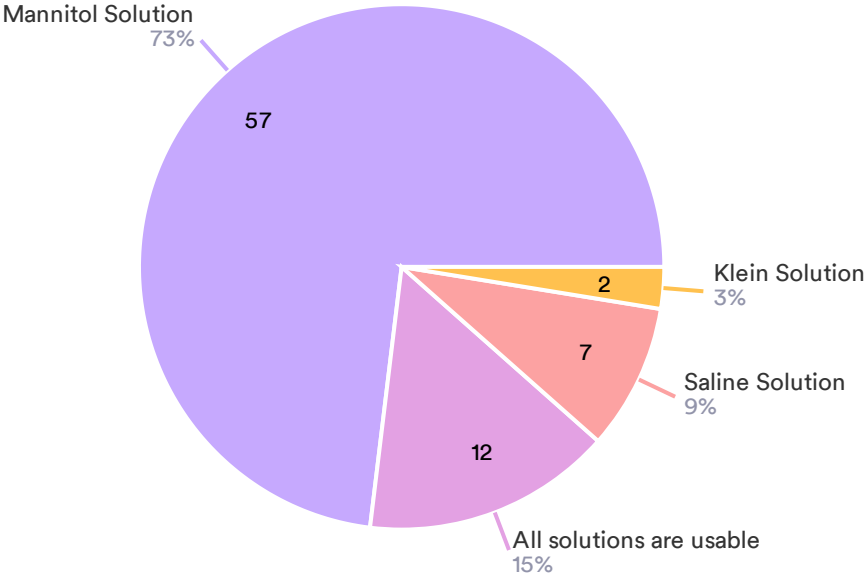
78 Responses



- High trans-sphincteric fistula
- Inter-sphincteric fistula
- Rectal submucosal abscess

3) During VAAFT the fistula tract is widened by

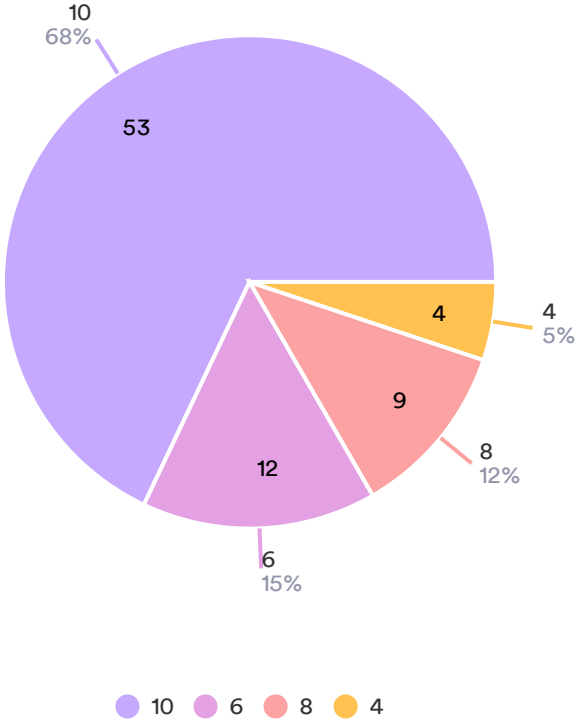
78 Responses



- Mannitol Solution
- All solutions are usable
- Saline Solution
- Klein Solution

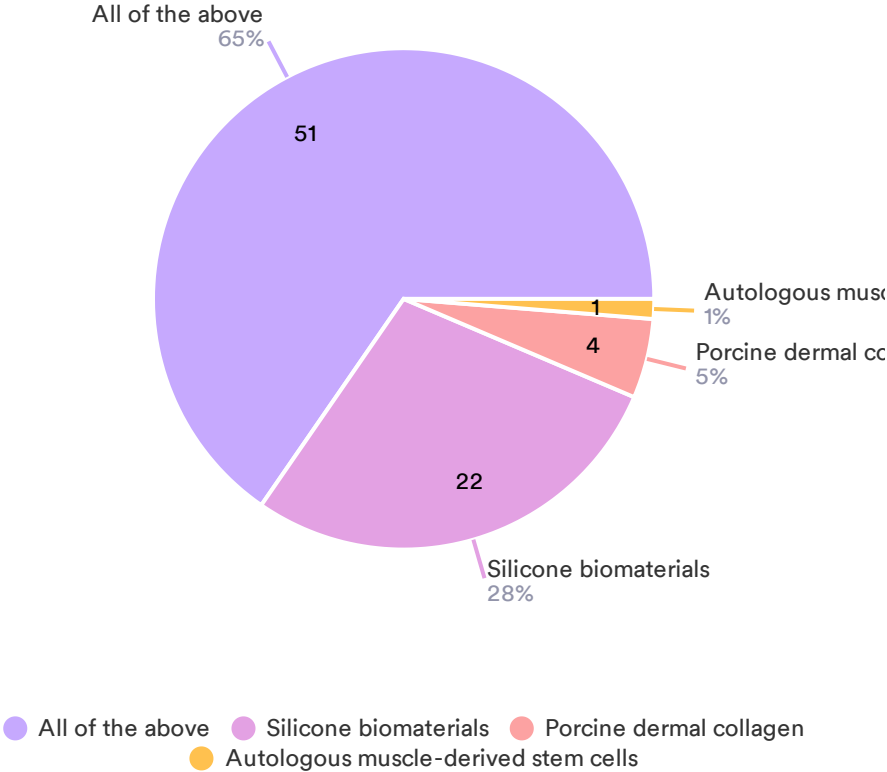
4) How many prostheses were implanted in the original description of SphinKeeper?

78 Responses



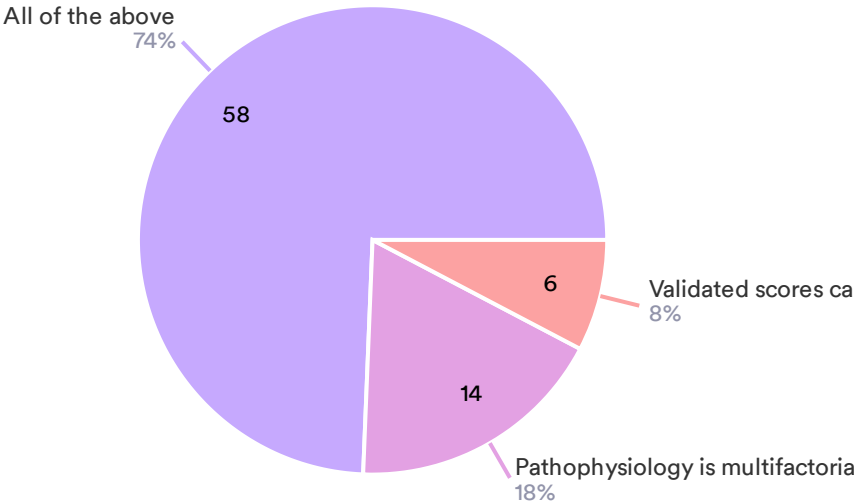
5) Which of the following is a bulking agent?

78 Responses



6) Please select the most correct answer regarding fecal incontinence:

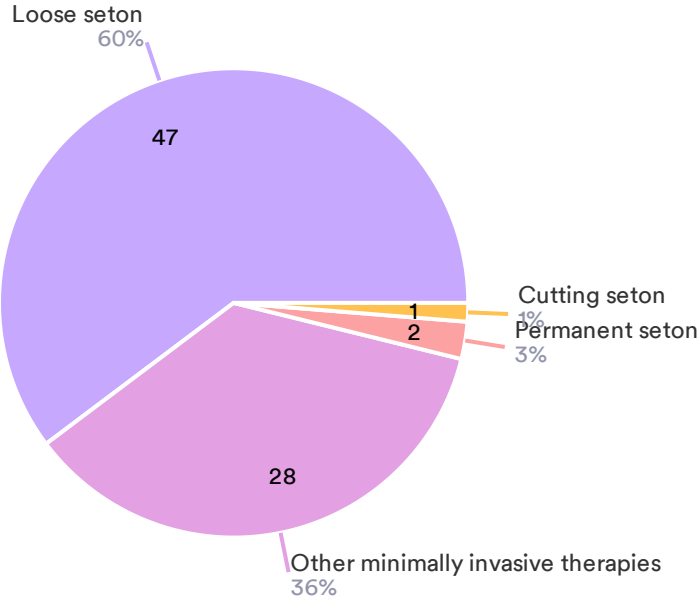
78 Responses



- All of the above
- Pathophysiology is multifactorial
- Validated scores can estimate the severity of symptoms

7) Which method is more suitable for high complex anal fistula? question

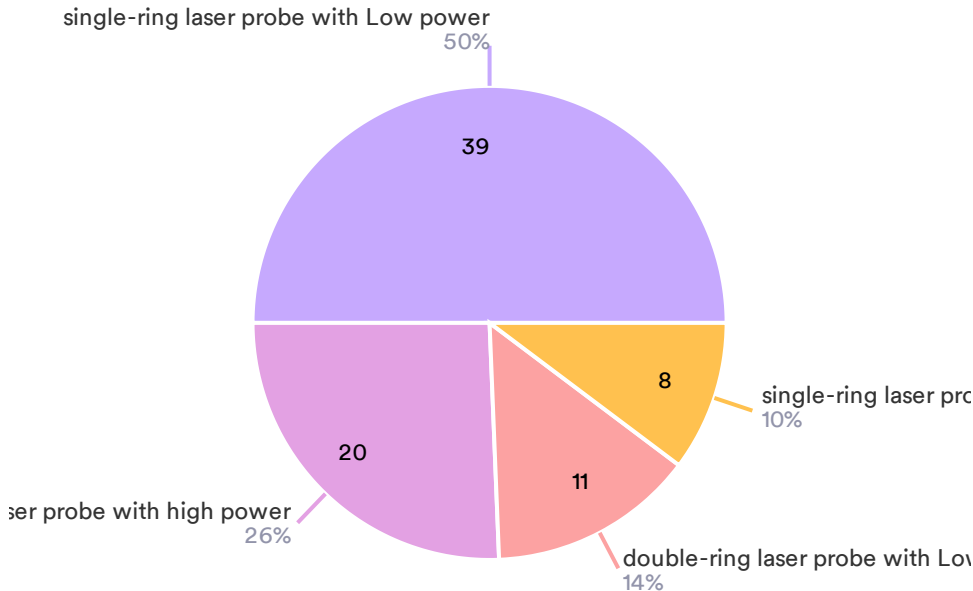
78 Responses



- Loose seton
- Other minimally invasive therapies
- Permanent seton
- Cutting seton

8) How to choose the laser probe and set the energy in FiLac ?

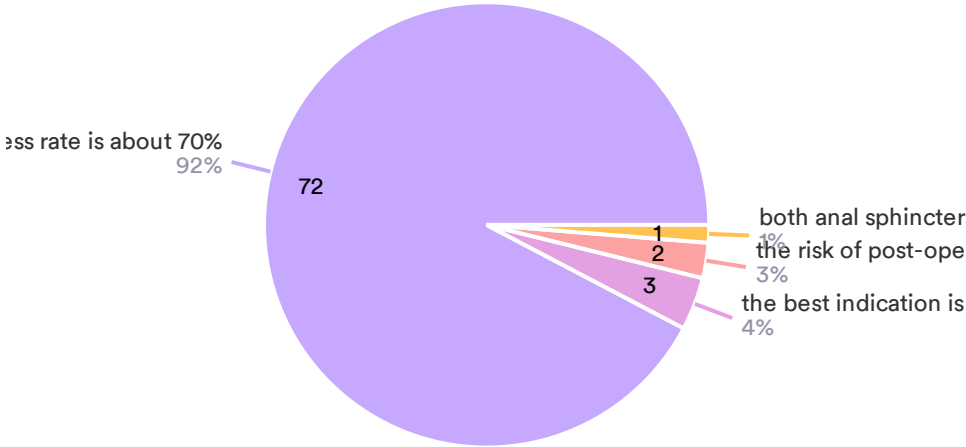
78 Responses



- single-ring laser probe with Low power
- double-ring laser probe with high power
- double-ring laser probe with Low power
- single-ring laser probe with high power

9) Concerning the “LIFT” (ligation of the intersphincteric fistula tract):

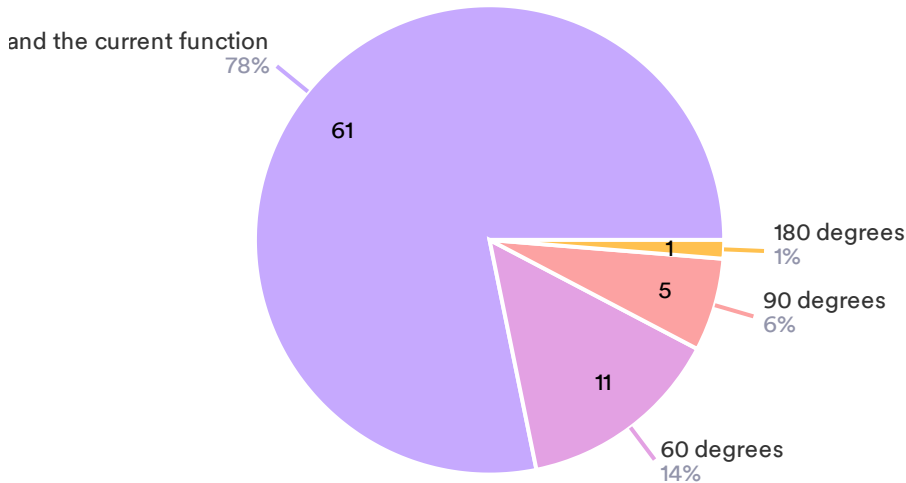
78 Responses



- the success rate is about 70%
- the best indication is perianal Crohn's disease
- the risk of post-operative fecal incontinence is 20%
- both anal sphincters are sectioned

10) What is the threshold of circumferential defect for sphincter repair?

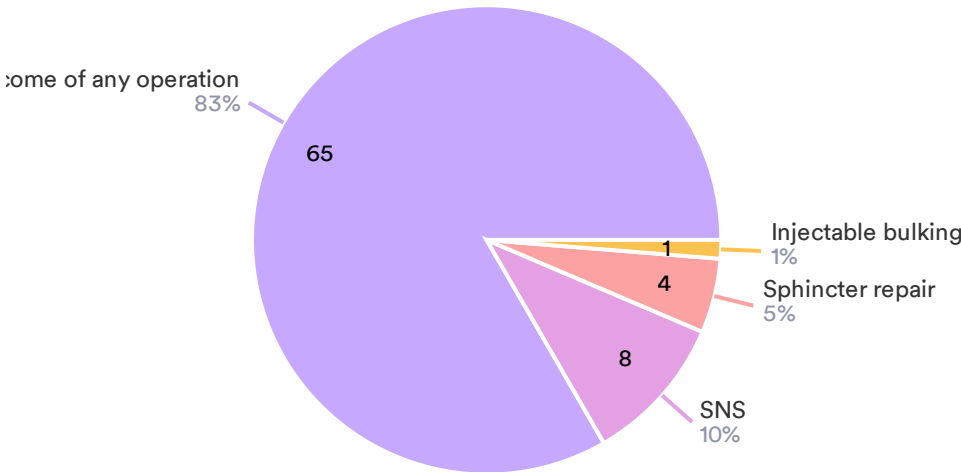
78 Responses



- No consensus and should take into account the time since injury was sustained and ...
- 60 degrees
- 90 degrees
- 180 degrees

11) Anorectal physiology testing can predict outcome of following surgery:

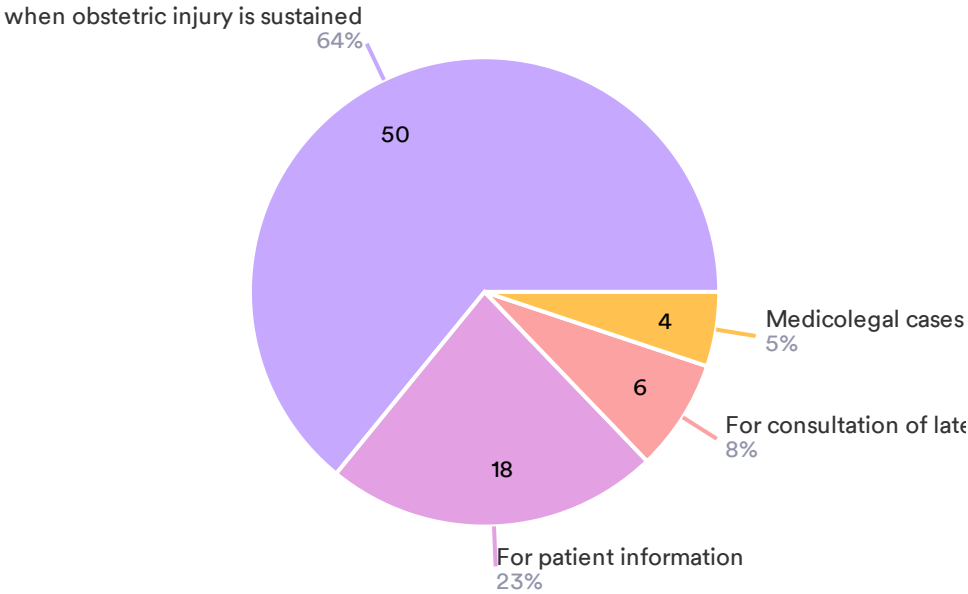
78 Responses



- Cannot predict outcome of any operation
- SNS
- Sphincter repair
- Injectable bulking agents

12) Anorectal physiology testing may be helpful in the following situations except:

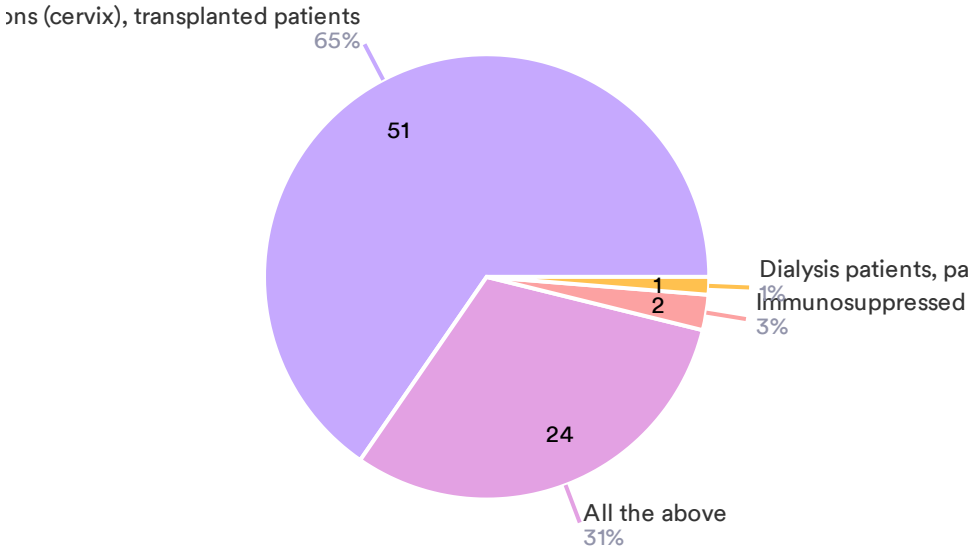
78 Responses



- At the time when obstetric injury is sustained
- For patient information
- For consultation of late missed obstetric injury
- Medicolegal cases

13) Which categories are at more risk for tumor (SCC) and need of specific screeni

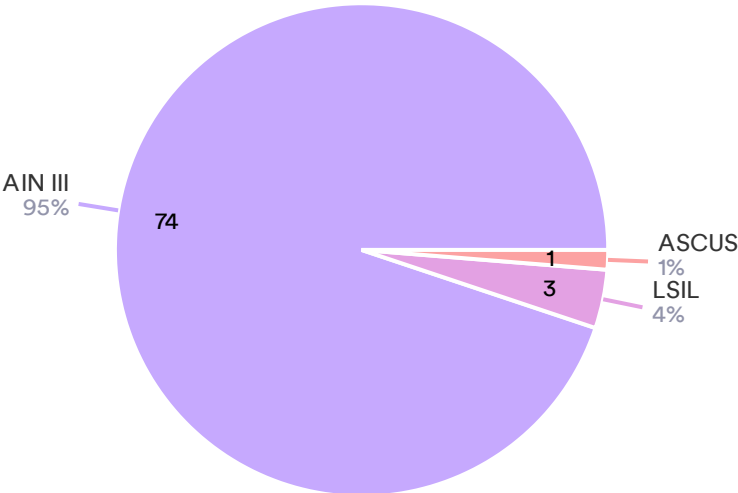
78 Responses



- HIV+MSM patients, women treated for HPV correlated lesions (cervix), transplanted patients
- All the above
- Immunosuppressed patients with TBC
- Dialysis patients, patients after gastrointestinal surgery

14) The most severe grade of anal dysplasia among the following cytologic and histologic specimen is:

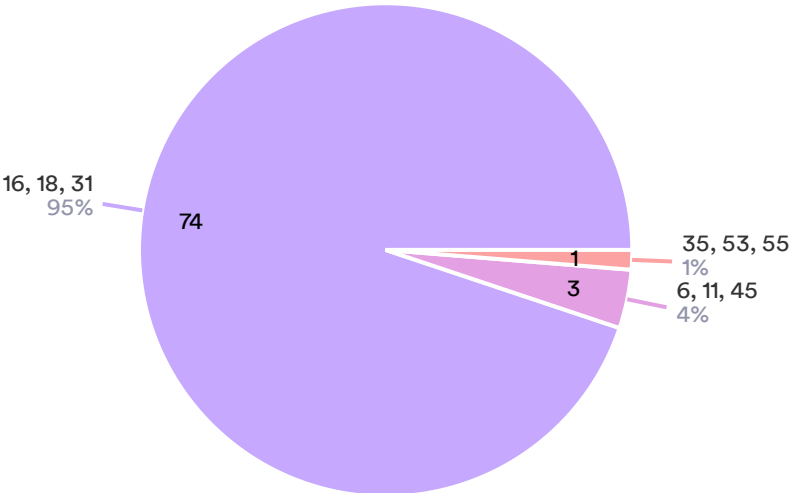
78 Responses



● AIN III ● LSIL ● ASCUS

15) Which ones of the following HPV genotypes are the most related to SCC?

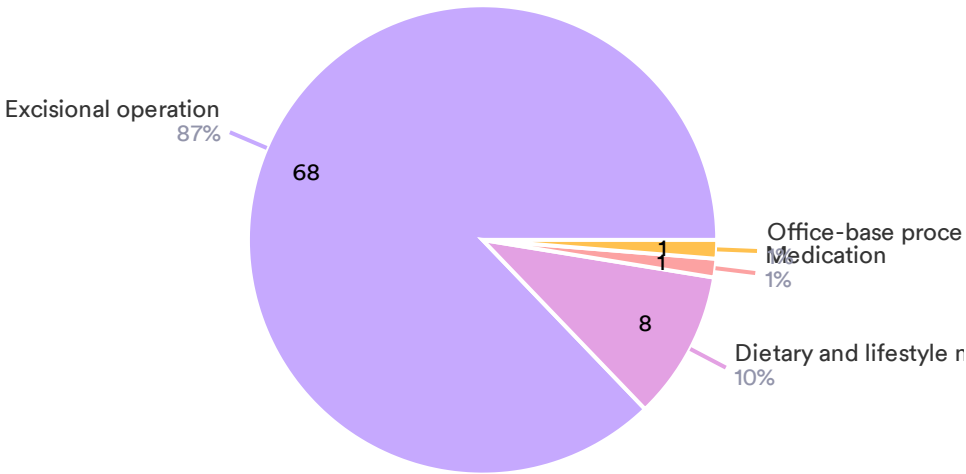
78 Responses



● 16, 18, 31 ● 6, 11, 45 ● 35, 53, 55

16) Which of the following techniques is not suitable for treatment of Grade I internal hemorrhoids?

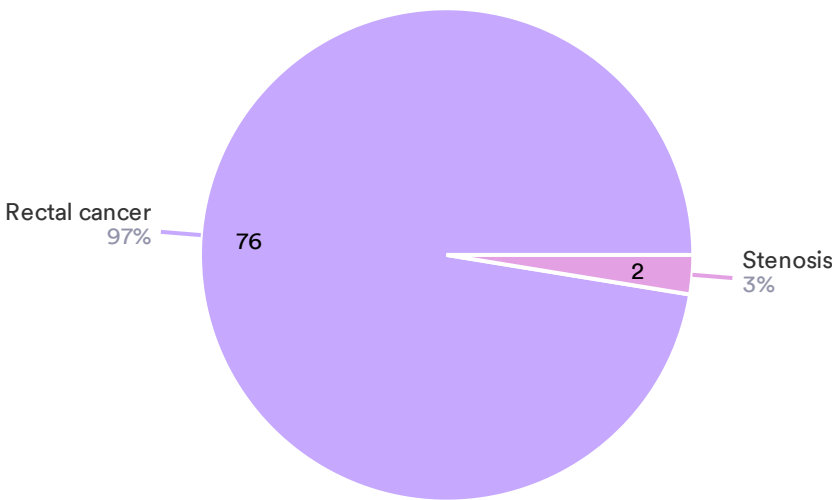
78 Responses



● Excisional operation ● Dietary and lifestyle modification ● Medication ● Office-base procedures

17) Which of the following is not a common complication of stapler therapy for hemorrhoids?

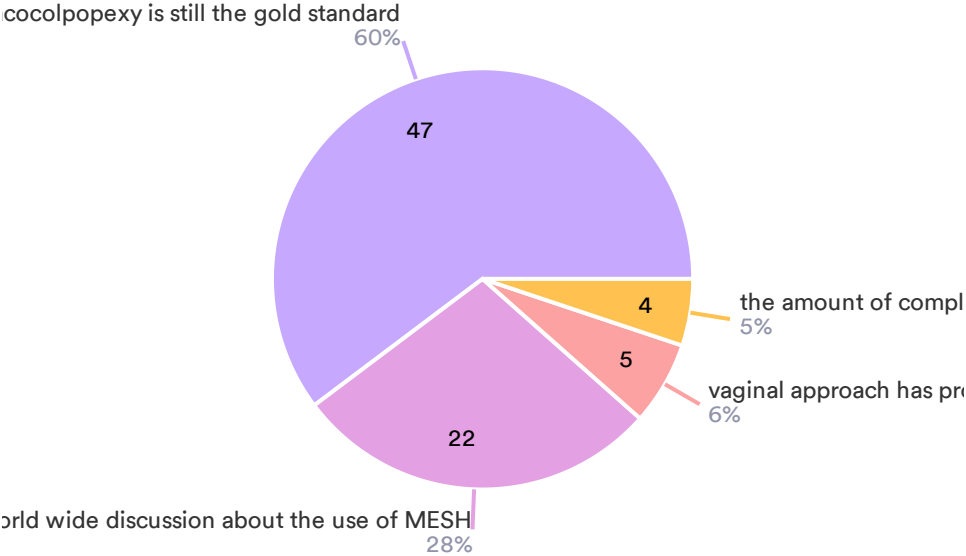
78 Responses



● Rectal cancer ● Stenosis

18) The gold standard for apical gynecological prolapse used to be a sacrocolpopexy. This has changed because of ?

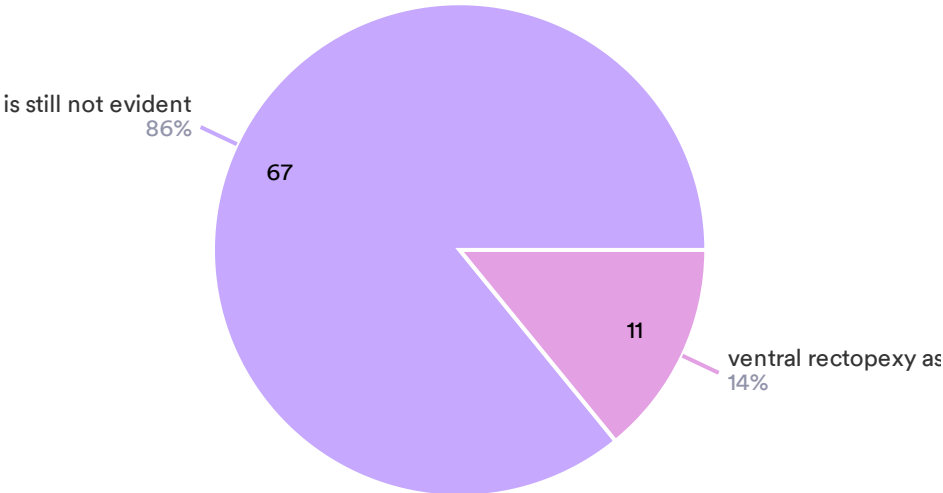
78 Responses



- this has not changed sacrocolpopexy is still the gold standard
- the world wide discussion about the use of MESH
- vaginal approach has proved to be better
- the amount of complications are too high

19) The new gold standard for the treatment of obstructed defecation is

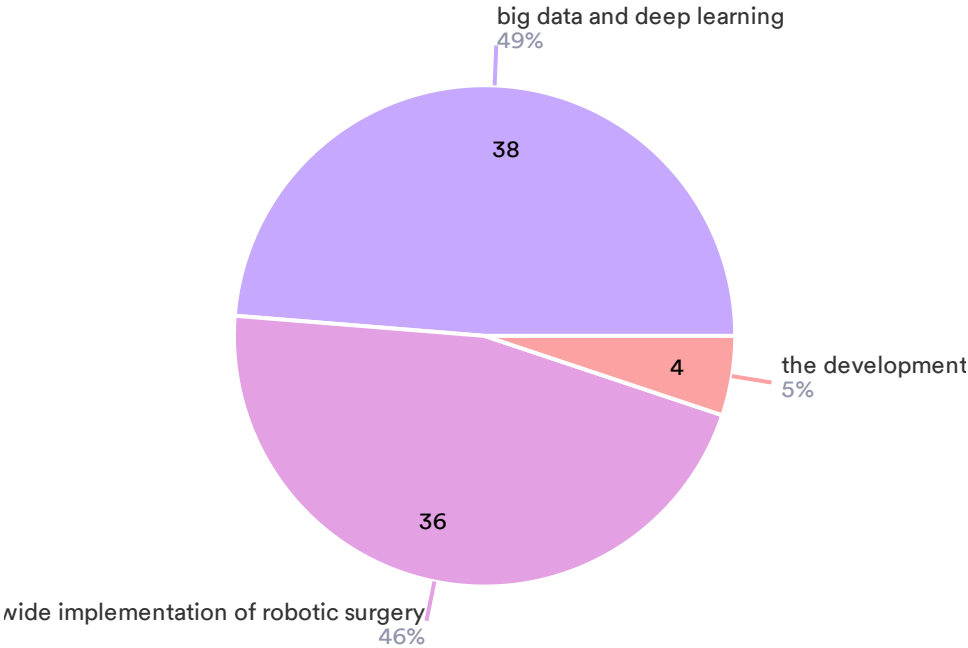
78 Responses



- is still not evident
- ventral rectopexy as described by d'hoore

20) The future of robotic surgery is mostly dependent of:

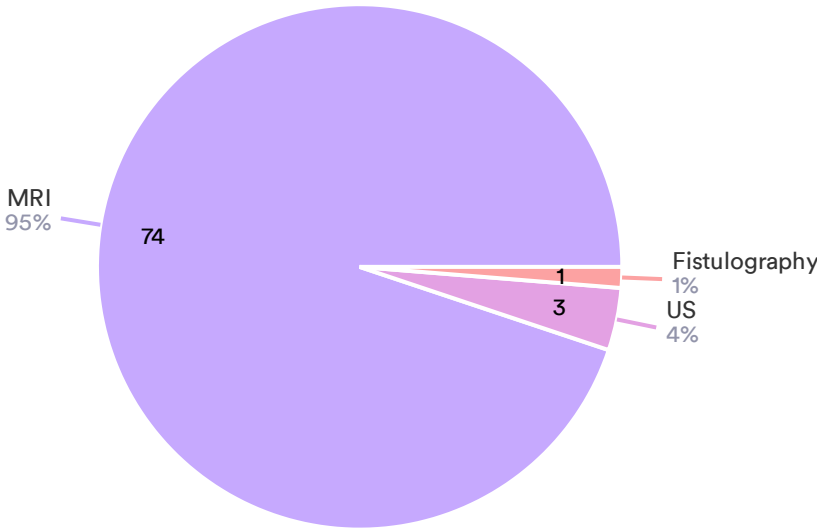
78 Responses



- big data and deep learning
- the world wide implementation of robotic surgery
- the development of new specific robotic surgical devices

21) The optimal imaging modality for complex fistula in ano is:

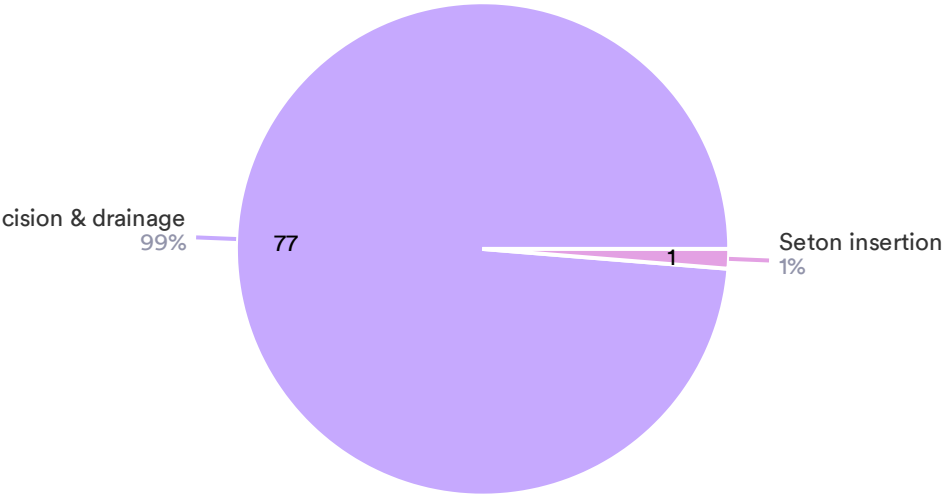
78 Responses



- MRI
- US
- Fistulography

22) In acute anorectal sepsis, the optimal treatment of the abscess is:

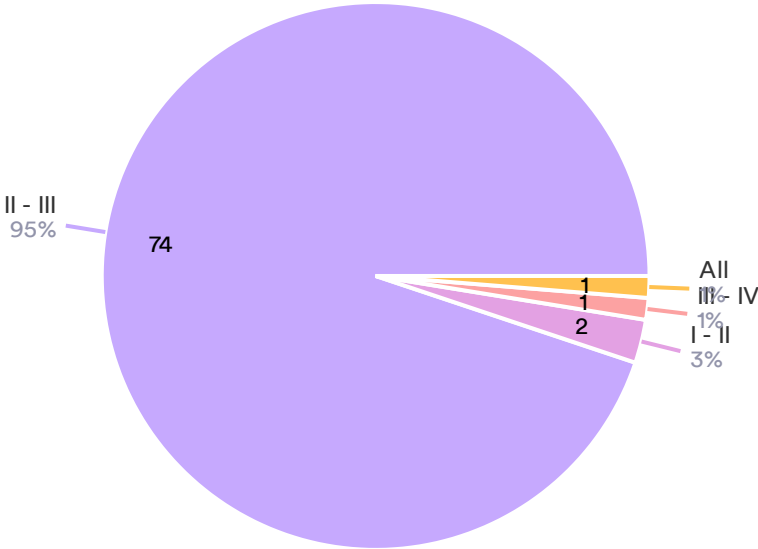
78 Responses



● Prompt incision & drainage ● Seton insertion

23) Which is the ideal grade of hemorrhoids to be treated with dearterialization?

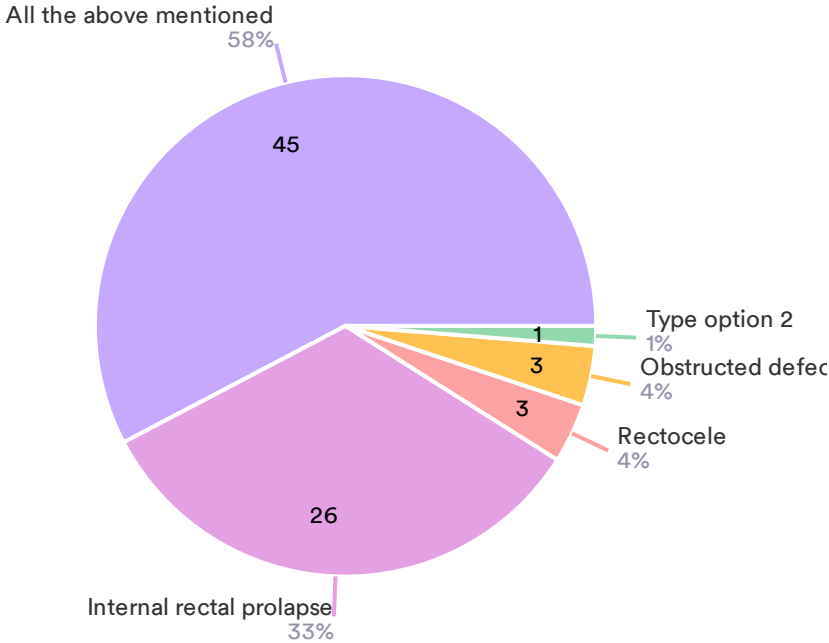
78 Responses



● II - III ● I - II ● III - IV ● All

24) Delorme procedure is suitable for:

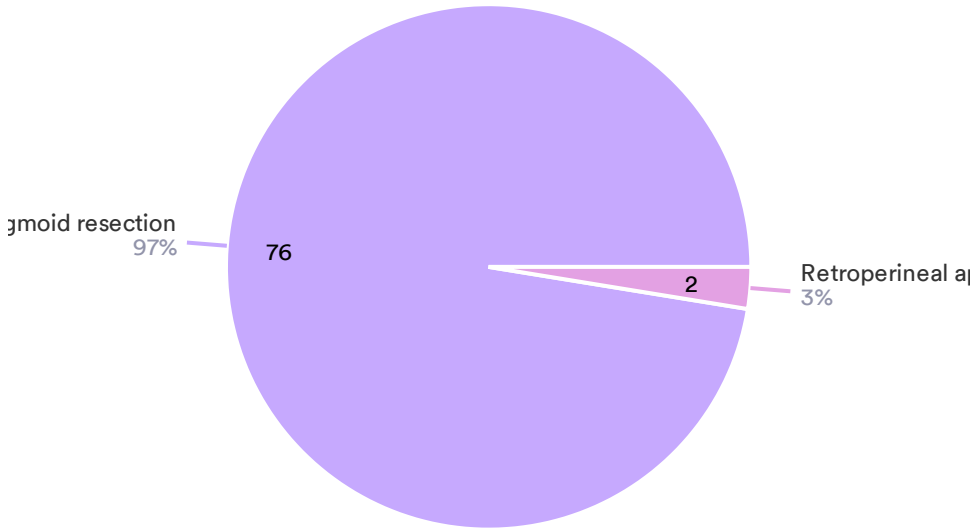
78 Responses



- All the above mentioned
- Internal rectal prolapse
- Rectocele
- Obstructed defecation
- Type option 2

25) Altemeier procedure consists in:

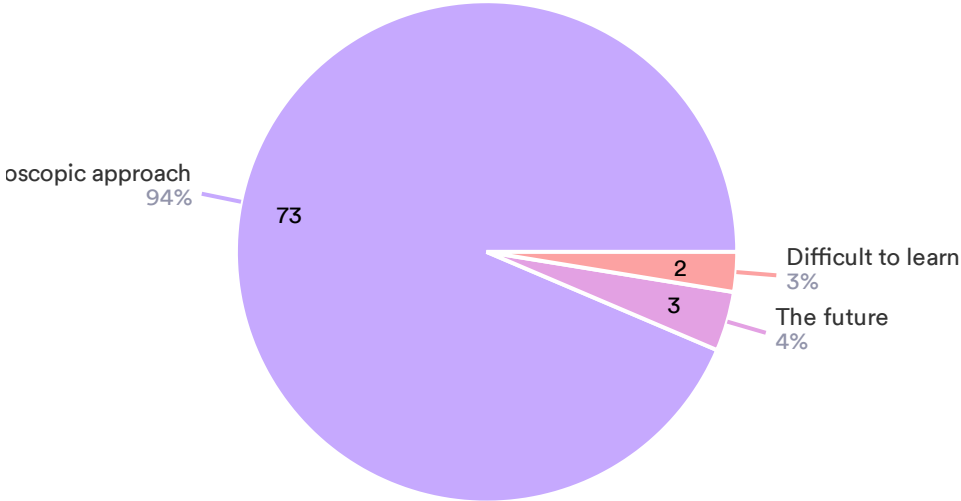
78 Responses



- Transanal recto-sigmoid resection
- Retroperineal approach

26) Robotic pelvic floor surgery is:

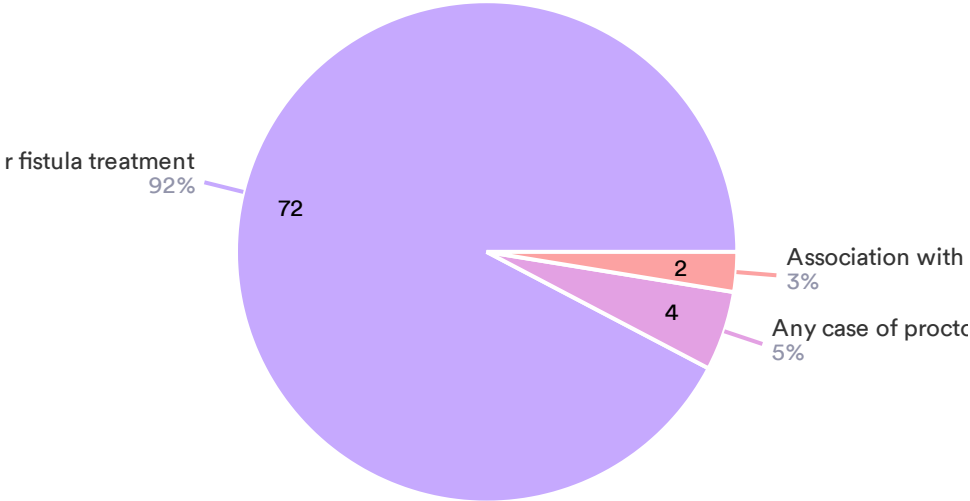
78 Responses



- A valid option with some advantages compared with laparoscopic approach
- The future
- Difficult to learn

27) Immunoregenerative surgery may be used in:

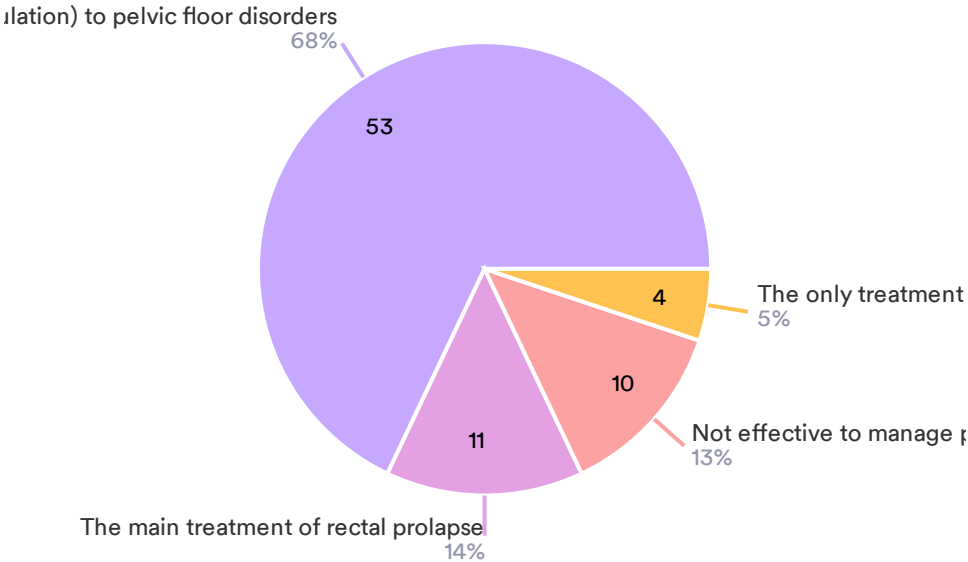
78 Responses



- Mainly for fistula treatment
- Any case of proctological diseases
- Association with bioprotetic materials

28) Pelvic floor rehabilitation is:

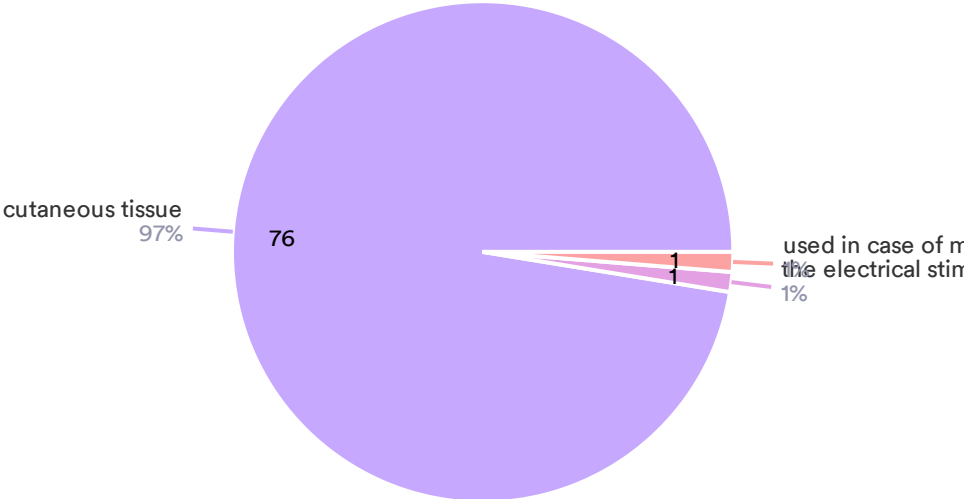
78 Responses



- A combined approach (FKT, biofeedback and electrostimulation) to pelvic floor disorders
- The main treatment of rectal prolapse
- Not effective to manage pelvic floor disorders
- The only treatment of anal incontinence

29) Neuro-sacral modulation is

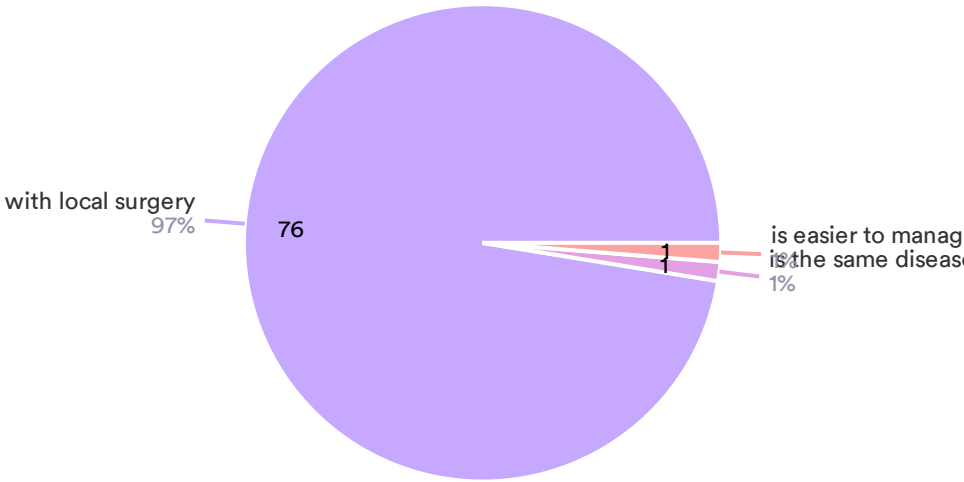
78 Responses



- Based on the placement of the lead electrode at the S3 sacral foramen connected to the electrical stimulation of the sphincters
- used in case of medullar lesions
- the electrical stimulation of the sphincters

30) Perianal fistulizing Crohn's disease:

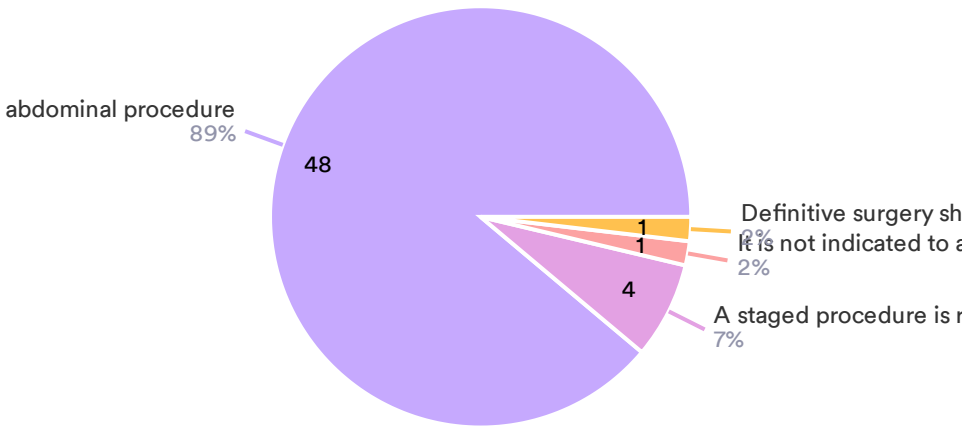
78 Responses



- needs a whole management of the disease in association with local surgery
- is the same disease of the cryptoglandular fistula
- is easier to manage than cryptoglandular fistula

31) In case of concomitant abdominal and perianal Crohn's disease (one of the following is correct):

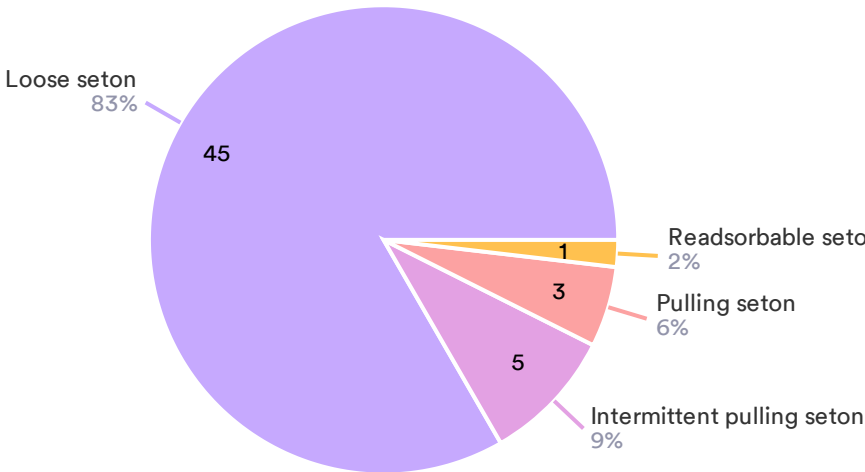
54 Responses- 24 Empty



- Drainage of the perianal sepsis should be accomplished along with the abdominal procedure
- A staged procedure is recommended for the abdominal procedure
- It is not indicated to associate the abdominal and the perianal surgical procedures
- Definitive surgery should be always provided for the perianal disease

32) Which is the recommended technique for seton placement in case of transphincteric fistula?

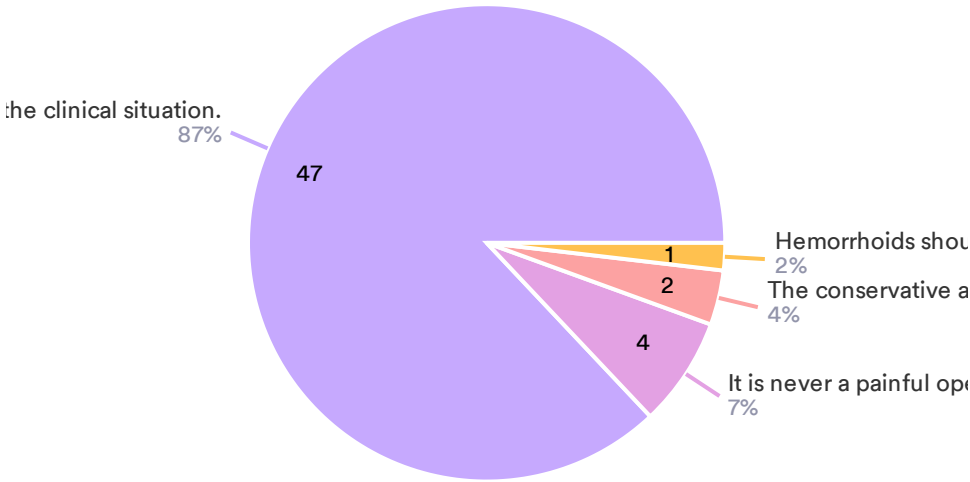
54 Responses- 24 Empty



- Loose seton
- Intermittent pulling seton
- Pulling seton
- Readsorbable seton

33) Regarding surgery for hemorrhoidal pathology:

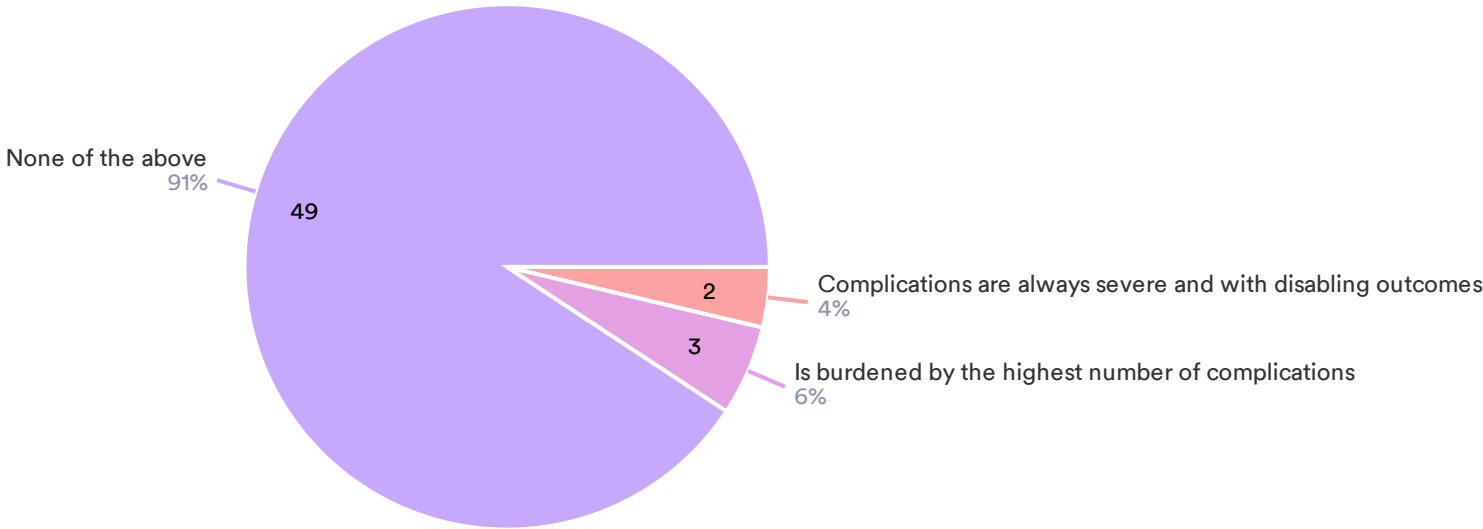
54 Responses- 24 Empty



- The choice depends on the surgeon's preference and on the clinical situation.
- It is never a painful operation
- The conservative approach is always better
- Hemorrhoids should always be removed to control symptoms

34) Axial stapler surgery of the rectum:

54 Responses- 24 Empty



● None of the above ● Is burdened by the highest number of complications ● Complications are always severe and with disabling outcomes

Thank You!